

# Conference Report - Management of HIV-Associated Lipoatrophy: Emerging Data in Clinical Context

Andrew Carr, MBBS, MD, FRACP, FRCPA

## Introduction

Of all the toxicities linked to antiretroviral therapy (ART), HIV lipodystrophy has been perhaps the most important from the perspective of patients. Lipodystrophy is a combination of peripheral, subcutaneous lipoatrophy with a lesser degree of relative fat accumulation in the abdomen, breasts, and upper trunk. This condition is cosmetically distressing and stigmatizing for many persons, and it is also associated with reduced adherence to ART.<sup>[1]</sup> Furthermore, it is associated with lipid and glycemic abnormalities, such as higher levels of total cholesterol and triglycerides, lower levels of high-density lipoprotein cholesterol, and insulin resistance and type 2 diabetes mellitus. These abnormalities are strongly linked to an increased risk for myocardial infarction and other atherosclerotic disease.<sup>[2]</sup>

This report focuses on clinical management issues associated with lipoatrophy. Although published data are cited throughout, particular attention is given to emerging data from the 8th International Workshop on Adverse Drug Reactions and Lipodystrophy in HIV, which was held September 24-26, 2006, in San Francisco, California. This relatively small conference has become one of the most important annual meetings devoted to original research on morphologic and metabolic disorders associated with HIV and its treatment.

## Treatment Issues

Since its identification, there has been substantial progress in describing the phenotype, risk factors, and natural history of lipodystrophy. There are now 3 major treatment-related issues specific to HIV lipoatrophy:

- how to prevent lipoatrophy;
- how to predict lipoatrophy in those at risk; and
- what to do about established lipoatrophy.

## How to Prevent Lipoatrophy

Prospective, randomized trials have found that antiretroviral treatment initiation with regimens containing abacavir + lamivudine (ABC/3TC) or tenofovir + emtricitabine (TDF/FTC) results in less lipoatrophy than regimens that contain stavudine (d4T) or zidovudine (AZT), particularly regimens containing d4T + didanosine (ddI).<sup>[3,4]</sup> Whether use of ABC/3TC or TDF/FTC causes any lipoatrophy at all is unknown and requires formal comparison with nucleoside

reverse transcriptase inhibitor (NRTI)-sparing regimens; the body-composition data from ACTG 5142 will be reported in early 2007 and should shed some light on this question.

The contribution of protease inhibitors (PIs) to lipoatrophy is unclear. Nelfinavir was associated with more lipoatrophy than efavirenz, each in combination with dual NRTIs, in the ACTG 384 body-composition substudy.<sup>[5]</sup> In contrast, the fat-friendly effects of ABC-3TC do not seem to be diminished by coadministration of a PI, and 3 PI switch studies found no improvement in lipoatrophy (although reductions in visceral adiposity were observed in one study).<sup>[6-8]</sup> Again, ACTG 5142 should further help our understanding of the relative contribution of certain antiretrovirals or antiretroviral drug classes to this adverse effect.

### **How to Predict Lipoatrophy**

Risk factors for lipoatrophy have mostly been identified from cross-sectional studies.<sup>[1]</sup> Factors identified consistently include:

- NRTI use (both type and duration);
- PI use and duration;
- prior AIDS diagnosis; and
- low CD4+ cell count.

(It is important to note that both prior AIDS diagnosis and low CD4+ cell count are perhaps surrogate markers for wasting and less baseline limb fat.)

In prospective studies, use of d4T, AZT, or indinavir (IDV) was most commonly associated with lipoatrophy risk. Unfortunately, most studies have not defined lipoatrophy objectively with body composition techniques such as dual-energy x-ray absorptiometry (DEXA), and no study has looked at whether any biomarker might predict objectively defined lipoatrophy.

At this year's Lipodystrophy Workshop, Calmy and colleagues<sup>[9]</sup> evaluated lipoatrophy objectively in 54 patients (53 men) who initiated various first-line ART regimens including 2 NRTIs (mostly d4T and ddI) and who had serial body-composition studies over 2 years. The investigators evaluated whether metabolic markers could predict long-term lipoatrophy development; they looked for associations between plasma markers and subsequent development of lipoatrophy (change in limb fat mass between weeks 24 and 96 by DEXA) and lipohypertrophy (increase in visceral adipose tissue [VAT] by abdominal CT through week 48). Using stored samples from 2 prospective studies that were collected at baseline and at weeks 12, 24, and 48, this group performed serial measurements of plasma adipokines, cytokines, lipids, and glycemic and acid-base parameters related to fat mass and lipodystrophy.

There were 2 findings of note from this study:

- Higher baseline body mass index and limb fat predicted greater loss of limb fat at week 96. This finding contrasts with cross-sectional studies that found lower limb fat to be a risk factor for lipoatrophy (and therefore, by inference, that starting earlier with higher limb fat somehow protects against lipoatrophy). The implication of these data is that lipoatrophy occurs in all patients, but that fat loss is greater in those with more fat at baseline.
- Increases in leptin\* levels at week 24 correlated with greater fat loss at week 96, which suggests that measuring leptin levels early in treatment might identify those patients at greatest risk for lipoatrophy.

*[\*Editor's note: Leptin is a peptide hormone transmitter produced only by fat cells and acts in muscle to promote insulin sensitivity and in the central nervous system to control appetite and, in turn, body fat mass.]*

### What to Do About Established Lipoatrophy

**Antiretroviral drug switches.** The main approach to improving or reducing the progression of lipoatrophy is to switch NRTIs, generally from d4T or AZT, to either ABC or TDF.<sup>[10,11]</sup> Switching antiretroviral drugs is most commonly done for one drug in a regimen for patients with complete viral suppression. ABC and TDF appear to allow for similar improvements in lipoatrophy, although the improvements observed at 1-2 years after these switches still are inadequate, with the mean gain in limb fat of approximately 400 g per year. *[Editor's note: See Dr. Graeme Moyle's report in this program for a graphic representation of these study data.]* To put this in perspective, this improvement is fairly modest if one considers that men with severe lipoatrophy have limb fat masses of about 3 kg and that normal limb fat mass for men is about 8 kg. (Unfortunately, there are minimal data for HIV-infected women or children.) These data suggest, therefore, that resolution of lipoatrophy might take 5 or even 10 years with this strategy alone.

**ART cessation.** The cessation of all ART has not been well studied, although this is no longer a strategy for most patients because of negative results that have been recently observed in a large trial evaluating CD4-guided strategic treatment interruptions. Kim and coworkers<sup>[12]</sup> evaluated adipose gene expression in subcutaneous abdominal fat following a 6-month interruption of all ART in 40 adults with suppressed HIV replication, including 29 of whom had available paired data:

- NRTIs+ PI (n = 10); NRTIs without PI (n = 19)
- d4T (n = 5) or AZT (n = 12); other NRTIs (n = 12)

The investigators evaluated adipose morphology, mitochondrial DNA, and adipose tissue gene expression. At 6 months, no subjective, clinical change in lipoatrophy was observed, although objective body-composition parameters were not measured. At 6 months, adipose fibrosis did not change, but there was less adipose inflammation such as fewer lipogranulomas and macrophages, fewer TNF-alpha or IL-6-staining cells, and less CD68 gene expression (CD68 is a macrophage-specific gene). There were also improvements in the expression of some mitochondrial genes (COX4 mRNA, and increased mtDNA and COX2/COX4 ratio).

Unfortunately, this study was not randomized, and patients were receiving very heterogeneous ART regimens, so the effects of specific antiretroviral drugs and drug classes were not clear. The major weakness, however, was the lack of body-composition data. Without these data, it is not clear whether any of the tissue changes might be associated with improvements in lipoatrophy, and it is even less clear whether there is an association with body-composition changes that are large enough to be objectively measured and clinically useful.

**Poly-L-lactic acid (PLA).** Injections of PLA are now licensed in the United States and Europe for cosmetic management of facial lipoatrophy. The drug appears to be safe,<sup>[13,14]</sup> but its efficacy is less clear, as no randomized trial of PLA with objective endpoints has been performed to determine how much PLA is required and for how long PLA maintains its benefit. The results of a randomized trial with objective endpoint data should be available in early 2007. PLA probably won't help the problem if the underlying cause is not removed, as lipoatrophy will continue to worsen in those taking drugs such as AZT and d4T, so PLA injections probably cannot take the place of d4T or AZT cessation. *[Editor's note: See Dr. Graeme Moyle's report on surgical/cosmetic interventions for HIV lipoatrophy within this program.]*

**Thiazolidinediones.** The first drugs explored for the treatment of HIV lipoatrophy were the thiazolidinediones, which are drugs that can make fat cells grow and that act by improving tissue insulin sensitivity. The best studied thiazolidinedione in patients with HIV is rosiglitazone.<sup>[15-17]</sup> Four randomized, placebo-controlled trials of rosiglitazone found improvements in insulin resistance but relatively unexpected deteriorations in total cholesterol and triglycerides.<sup>[1]</sup> Three of the studies found no significant improvement in limb fat mass, although one found a benefit at 6 months in those not receiving d4T or AZT that was lost by 12 months.

Pioglitazone was subsequently reported as an effective treatment for HIV lipoatrophy in a randomized, placebo-controlled study conducted by the ANRS in France and first presented at the 13th Conference on Retroviruses and Opportunistic Infections (CROI) in 2006.<sup>[18]</sup> The mean improvement in limb fat mass over 48 weeks was about 0.3 kg, with the benefit largely confined to those

persons not receiving d4T. At this year's Lipodystrophy Workshop, Maachi and associates<sup>[19]</sup> presented additional metabolic data from this study. No significant changes in plasma levels of leptin, resistin\*, and soluble TNF receptor I (sTNFRI)\* were observed at week 48 in the pioglitazone group as compared with the placebo group. In contrast, plasma adiponectin\* levels increased by about 150% with pioglitazone relative to placebo. Of interest, this effect was observed both in patients not receiving and receiving d4T. The change of limb fat mass between baseline and week 48 correlated with both plasma pioglitazone concentration ( $r = 0.476$ ,  $P < .001$ ,  $n = 51$ ). Given the availability of a higher dose of pioglitazone (45 mg tablet given once daily) than was used in this study (30 mg once daily), perhaps a higher dose warrants study and might be more effective. Overall, the results of this study support the use of pioglitazone in the treatment of peripheral lipoatrophy in HIV-infected adults, but the relatively modest effect observed in fat gain means that pioglitazone is no substitute for cessation of d4T or AZT.

[\*Editor's note:

- *Resistin causes cells to be less sensitive to insulin.*
- *TNF-alpha also downregulates insulin sensitivity (it antagonizes leptin and adiponectin), and the level of its soluble receptor in plasma is linked to insulin sensitivity.*
- *Adiponectin is another adipocyte cytokine that, with leptin, promotes insulin sensitivity in muscle and liver. Low levels of adiponectin are associated with accelerated cardiovascular disease.]*

**Uridine.** In-vitro studies pioneered by Ulrich Walker<sup>[20]</sup> have found that the mitochondrial toxicity of AZT and d4T could be prevented and reversed in fat cell culture by uridine, even in the presence of ongoing AZT or d4T exposure. Uridine is a substance required for the synthesis of pyrimidines, which are building blocks of DNA and RNA. A small, randomized, placebo-controlled study in 20 adults receiving AZT or d4T showed that limb fat increased significantly by a mean 700 g over only 12 weeks.<sup>[21]</sup> Provided that these data can be replicated in larger and longer studies currently in progress, the main question relating to uridine will be whether it can still exert benefit in those who are no longer receiving d4T or AZT. This is very important given that d4T is barely used in developed countries and AZT use is declining, particularly in light of the Gilead 934 study showing superiority of TDF over 48 weeks on an intention-to-treat basis.<sup>[22]</sup> Unfortunately, uridine is not licensed in North America, but can be imported at considerable expense (about US\$300 per month). This considerable expense precludes use of the drug in the developing world.

**Pravastatin.** One unexpected positive therapeutic outcome for lipoatrophy has come in the form of pravastatin, a drug widely used for the treatment of high cholesterol levels for the primary and secondary prevention of cardiovascular disease. In a randomized, placebo-controlled, 12-week trial, pravastatin did not have much effect on cholesterol levels in men receiving ART (mostly including a ritonavir-boosted PI without d4T or AZT).<sup>[23]</sup> As with uridine, however, limb fat mass increased significantly (by about 500 g), again a far greater increase than seen with NRTI switch strategies over 48 weeks. Although the mechanism of action is unknown, we know that the drug is safe and, in particular, has few HIV drug interactions (with the exception of darunavir). What we really need to know is whether this statin or other statins will show benefits over longer periods.

**Other interventions under study.** No new treatment intervention for lipoatrophy was reported at this year's Workshop. However, Boccara and colleagues<sup>[24]</sup> reported on the effects of irbesartan in an in-vitro model of ART-induced lipoatrophy (3T3-F442A murine adipocytes). Irbesartan is an antihypertensive angiotensin II type 1 receptor blocker that recently was shown to activate peroxisome proliferator-activated receptor gamma (PPAR-gamma) in adipocytes and to reduce the incidence of diabetes mellitus in hypertensive patients. PPAR-gamma is a key adipocyte differentiating and maturation factor, and its expression is reduced in HIV lipoatrophy. The investigators found that irbesartan suppressed the adverse effects of IDV and of ritonavir boosted-atazanavir (ATV/r) on lipogenesis and lipid accumulation, but not of ritonavir boosted-lopinavir (LPV/r). Irbesartan also prevented IDV and ATV/r-induced insulin resistance (normalizing insulin-induced tyrosine phosphorylation [ie, activation] of the insulin receptor and insulin-mediated glucose transport), as well as the expression of 2 major proteins, CCAAT-enhancer-binding protein (C/EBP)-alpha and PPAR-gamma, which are involved in adipogenesis and the insulin response.

These data suggest that irbesartan may prevent or even treat the lipoatrophy and insulin resistance induced by some HIV PIs. The relevance of the dose used, however, was not clear; a pilot study in humans seems justified. The effects of NRTIs were not evaluated, which is unfortunate as NRTIs clearly have more of a lipoatrophic effect than PIs and because NRTIs also inhibit PPAR-gamma expression. The effects of other angiotensin II type 1 receptor blockers also deserve investigation.

Another drug that has been of some interest in the management of HIV lipoatrophy is leptin, an adipocytokine (a key adipocyte-produced hormone). Leptin levels may be low in HIV lipodystrophy, but because it is a fat cell product rather than a fat cell stimulant whose plasma levels are low in HIV lipodystrophy, it seems unlikely that leptin would improve lipoatrophy. However, it might well improve the downstream insulin resistance and dyslipidemia associated with the leptin deficiency that is seen in congenital and other acquired lipodystrophies.

Khatami and colleagues<sup>[25]</sup> performed an open-label study to determine whether leptin could produce similar metabolic benefits in HIV-infected patients with lipoatrophy. Eight men with HIV lipoatrophy, low plasma leptin levels (< 3 ng/mL), dyslipidemia, and insulin resistance received leptin for 6 months (0.01 mg/kg twice daily for 3 months, followed by 0.03 mg/kg twice daily for 3 months). Hepatic insulin sensitivity improved (reduce fasting insulin of about 20%) as did endogenous glucose production, glycogenolysis, and gluconeogenesis. However, there was no significant change in peripheral glucose uptake in fat or muscle, nor in limb fat mass, although lipolysis (breakdown) of fat declined somewhat, which suggests an effect of leptin on adipose tissue. Visceral fat decreased by about 30% (183 to 129 cm<sup>2</sup>;  $P = .001$ ); this improvement without a decline in limb fat suggests that leptin may have a depot-specific effect in adipose tissue.

*Supported by an independent educational grant from Gilead.*

## References

1. Grinspoon SK, Carr A. Cardiovascular risk and body fat abnormalities in HIV-infected adults. *N Engl J Med.* 2005;352:48-62. [Abstract](#)
2. Friis-Moller N, Sabin CA, Weber R, et al. Combination antiretroviral therapy and the risk of myocardial infarction. *N Engl J Med.* 2003;349:1993-2003. [Abstract](#)
3. Shlay JC, Visnegarwala F, Bartsch G, et al. Body composition and metabolic changes in antiretroviral-naive patients randomized to didanosine and stavudine vs. abacavir and lamivudine. *J Acquir Immune Defic Syndr.* 2005;38:147-155. [Abstract](#)
4. Law M, Puls R, Cheng AK, Cooper DA, Carr A. Evaluation of the HIV lipodystrophy case definition in a placebo-controlled, 144-week trial in antiretroviral-naïve adults. *Antivir Ther.* 2006;11:179-186. [Abstract](#)
5. Dube M, Kamarow L, Mulligan, et al. DEXA outcomes in antiretroviral-naive subjects randomized to nelfinavir or efavirenz or both plus dual nucleosides: long-term results from A5005s, a substudy of ACTG 384. Program and abstracts of the XVI International AIDS Conference; August 13-18, 2006; Toronto, Ontario, Canada. Abstract WEPE0167.
6. Carr A, Hudson J, Chuah J, et al, for the PIILR investigators. HIV protease inhibitor substitution in patients with lipodystrophy: a randomised, multicentre, open-label study. *AIDS.* 2001;15:1811-1822. [Abstract](#)
7. Ruiz L, Negredo E, Domingo P, et al, for the Spanish Lipodystrophy Group. Antiretroviral treatment simplification with nevirapine in protease inhibitor-experienced patients with HIV-associated lipodystrophy: 1-year prospective follow-up of a multicenter, randomized, controlled study. *J Acquir Immune Defic Syndr.* 2001;27:229-236. [Abstract](#)
8. John M, McKinnon EJ, James IR, et al. Randomized, controlled, 48-week study of switching stavudine and/or protease inhibitors to combivir/abacavir to

- prevent or reverse lipoatrophy in HIV-infected patients. *J Acquir Immune Defic Syndr.* 2003;33:29-33. [Abstract](#)
9. Calmy A, Carey D, Mallon P, et al. Early changes in adiponectin and leptin levels predict changes limb fat mass over two years following initiation of antiretroviral therapy. Program and abstracts of the 8th International Workshop on Adverse Drug Reactions and Lipodystrophy in HIV; September 24-26, 2006; San Francisco, California. Abstract 16.
  10. Martin A, Smith D, Carr A, et al, MITOX study group. Changes in lipodystrophy 2 years after switching from thymidine nucleoside analogues to abacavir. *AIDS.* 2004;18:1029-1036. [Abstract](#)
  11. Moyle GJ, Sabin CA, Cartledge J, et al, for the RAVE (Randomized Abacavir versus Viread Evaluation) group UK. A randomized comparative trial of tenofovir DF or abacavir as replacement for a thymidine analogue in persons with lipoatrophy. *AIDS.* 2006;20:2043-2050. [Abstract](#)
  12. Kim M, Leclercq P, Cervera P, et al. A 6-month ART interruption in HIV-infected patients improves adipose tissue morphology and gene expression (ANRS EP29 Lipostop). Program and abstracts of the 8th International Workshop on Adverse Drug Reactions and Lipodystrophy in HIV; September 24-26, 2006; San Francisco, California. Abstract 5.
  13. Valantin MA, Aubron-Olivier C, Ghosn J, et al. Polylactic acid implants (New-Fill) to correct facial lipoatrophy in HIV-infected patients: results of the open-label study VEGA. *AIDS.* 2003;17:2471-2477. [Abstract](#)
  14. Moyle GJ, Lysakova L, Brown S, et al. A randomized open-label study of immediate versus delayed polylactic acid injections for the cosmetic management of facial lipoatrophy in persons with HIV infection. *HIV Med.* 2004;5:82-87. [Abstract](#)
  15. Carr A, Workman C, Carey D, et al, for the Rosey investigators. No effect of rosiglitazone for HIV-1 lipoatrophy: a randomised, double-blind, placebo-controlled trial. *Lancet.* 2004;363:429-438. [Abstract](#)
  16. Hadigan C, Yawetz S, Thomas A, Havers F, Sax PE, Grinspoon S. Metabolic effects of rosiglitazone in HIV lipodystrophy: a randomized, controlled trial. *Ann Intern Med.* 2004;140:786-794. [Abstract](#)
  17. Sutinen J, Hakkinen AM, Westerbacka J, et al. Rosiglitazone in the treatment of HAART-associated lipodystrophy--a randomized double-blind placebo-controlled study. *Antivir Ther.* 2003;8:199-207. [Abstract](#)
  18. Slama L, Lanoy E, Valantin MA, et al. Effect of pioglitazone on HIV-1 related lipoatrophy: a randomized double-blind placebo-controlled trial (ANRS 113) with 130 patients. Program and abstracts of the 13th Conference on Retroviruses and Opportunistic Infections; February 5-8, 2006; Denver, Colorado. Abstract 151LB.
  19. Maachi M, Slama L, Lanoy E, et al. Effect of pioglitazone on limb fat and circulating adipokines in HIV-related lipodystrophy (ANRS113:Lipiot). Program and abstracts of the 8th International Workshop on Adverse Drug Reactions and Lipodystrophy in HIV; September 24-26, 2006; San Francisco, California.

- Abstract 23.
20. Walker UA, Langmann P, Miehle N, Zilly M, Klinker H, Petschner F. Beneficial effects of oral uridine in mitochondrial toxicity. *AIDS*. 2004;18:1085-1086. [Abstract](#)
  21. Sutinen J, Walker UA, Sevastianova K, Hakkinen AM, Ristola M, Yki-Jarvinen H. Uridine supplementation increases subcutaneous fat in patients with HAART -- associated lipodystrophy (HAL) -- a randomized, placebo-controlled trial. Program and abstracts of the 7th International Workshop on Adverse Events and Lipodystrophy in HIV; November 13-16, 2006; Dublin, Ireland. Abstract 7.
  22. Pozniak AL, Gallant JE, Dejesus E, et al, for the Study 934 Group. Tenofovir disoproxil fumarate, emtricitabine, and efavirenz versus fixed-dose zidovudine/lamivudine and efavirenz in antiretroviral-naive patients: virologic, immunologic, and morphologic changes: a 96-week analysis. *J Acquir Immune Defic Syndr*. 2006 [Epub ahead of print].
  23. Mallon PWG, Miller J, Kovacic JC, et al. Effects of pravastatin on body composition and markers of cardiovascular disease in HIV-infected men: a randomised, placebo-controlled study. *AIDS*. 2006;20:1003-1010. [Abstract](#)
  24. Boccara F, Caron M, Auclair M, Capeau J. Irbesartan, an angiotensin II receptor I blocker, prevents the adverse effects of HIV antiretrovirals on adipocyte functions. Program and abstracts of the 8th International Workshop on Adverse Drug Reactions and Lipodystrophy in HIV; September 24-26, 2006; San Francisco, California. Abstract 7
  25. Khatami H, Mulligan K, Schwarz J, et al. Effects of leptin treatment on glucose and lipid metabolism and fat distribution in HIV-infected patients with lipoatrophy and hypoleptinemia. Program and abstracts of the 8th International Workshop on Adverse Drug Reactions and Lipodystrophy in HIV; September 24-26, 2006; San Francisco, California. Abstract 21.

## Expert Column - Cosmetic Interventions for HIV-Associated Lipoatrophy

Graeme J. Moyle, MD, MBBS

### Introduction

The development of facial changes associated with generalized lipoatrophy during antiretroviral therapy is perceived by patients as a highly stigmatizing manifestation of their HIV infection. These facial changes may lead to the unmasking of HIV status to colleagues, affect social and personal relationships, and suggest that an individual who is otherwise healthy is unwell.<sup>[1]</sup> It has been reported not only to affect mood and quality of life, but also to reduce adherence to antiretroviral medication. Lipoatrophy in other body areas may also lead to changes in personal confidence and habits.

## Lipoatrophy: Prevention Is the Best Policy

Lipoatrophy appears to be a preventable toxicity that is largely restricted to individuals who have received prolonged therapy with thymidine analogue nucleoside reverse transcriptase inhibitors (NRTIs). Use of thymidine analogs in combination with (certain) protease inhibitors (PIs) may accelerate the rate of fat loss. Prospective data from studies in which persons have begun regimens with thymidine-sparing NRTI backbones (Table 1) -- such as abacavir-lamivudine, tenofovir-lamivudine, tenofovir-emtricitabine, and didanosine-emtricitabine -- have reported few instances of lipoatrophy, even over prolonged follow-up. These data offer hope that in the future, the incidence of lipoatrophy observed in clinical practice will decline relative to the prevalence currently observed among HIV-infected persons who have a treatment history that includes a regimen containing a thymidine analogue NRTI plus a PI.

**Table 1. Nucleoside Reverse Transcriptase Inhibitors (NRTIs) for the Treatment of HIV Infection**

Thymidine analogue NRTIs (single agents)	Coformulated, fixed-dose NRTIs (containing a thymidine analogue NRTI)	Non-thymidine analogue NRTIs (single agents)	Coformulated, fixed-dose NRTIs (not containing a thymidine analogue NRTI)
stavudine zidovudine	lamivudine + zidovudine  abacavir + lamivudine + zidovudine	abacavir  didanosine  emtricitabine  lamivudine tenofovir DF	abacavir + lamivudine  tenofovir DF + emtricitabine  efavirenz* + emtricitabine + tenofovir DF

\*This coformulated tablet also contains efavirenz, an NNRTI, in addition to 2 NRTIs.

**Pharmacologic strategies to manage lipoatrophy.** The only approach to management of lipoatrophy that has demonstrated benefit in 2 or more controlled clinical trials is switching therapy away from a thymidine analogue NRTI. Alternatives to thymidine analogue NRTIs include abacavir, tenofovir, or NRTI-sparing antiretroviral regimens. While recovery of peripheral fat mass can be detected by dual-energy x-ray absorptiometry (DEXA) scanning, these studies did not report impressive clinical recovery or subjective improvements in fat gain. The rate of limb fat recovery appears similar with each of these approaches, with comparative data from the RAVE switch study<sup>[2]</sup> observing similar recovery with switch from a thymidine analog to abacavir or tenofovir DF (Figures 1 and 2). Of

note, some individuals experience little of no limb fat recovery over 48 weeks, suggesting that for some individuals lipoatrophy may not be reversible (Figure 3). Laser facial imaging, reported from a subset of patients in the RAVE study, indicated that cheek volumes also increased over 48 weeks (Figure 4).<sup>[3]</sup> Changes in cheek volume were noted to correlate with limb fat recovery.

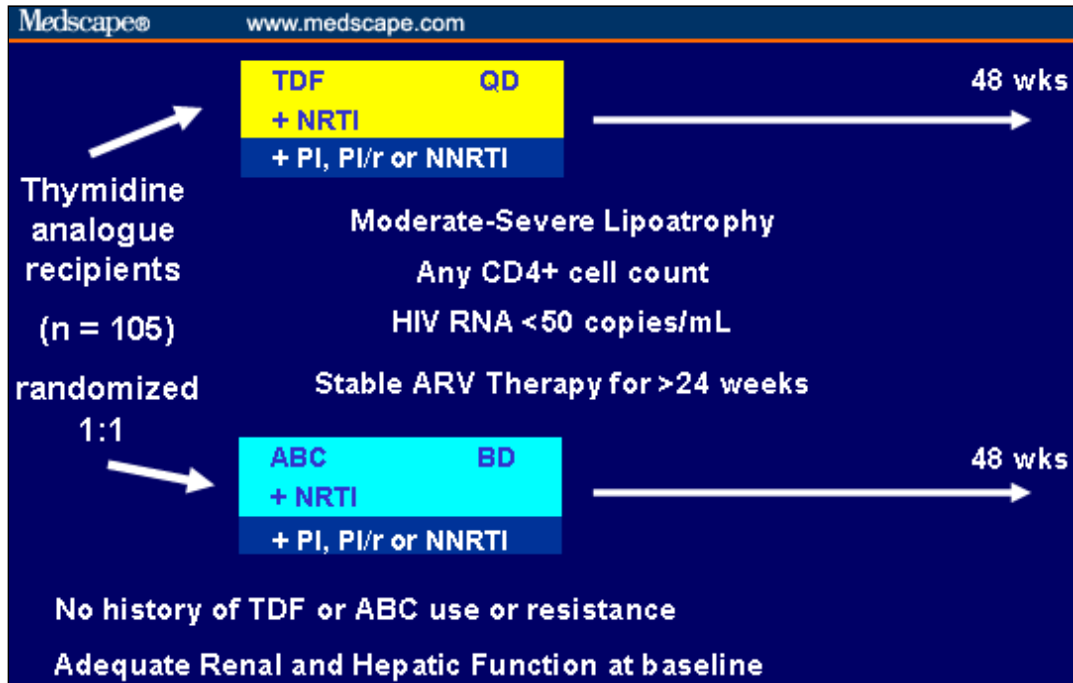


Figure 1. Design of the RAVE switch study.<sup>[2]</sup>

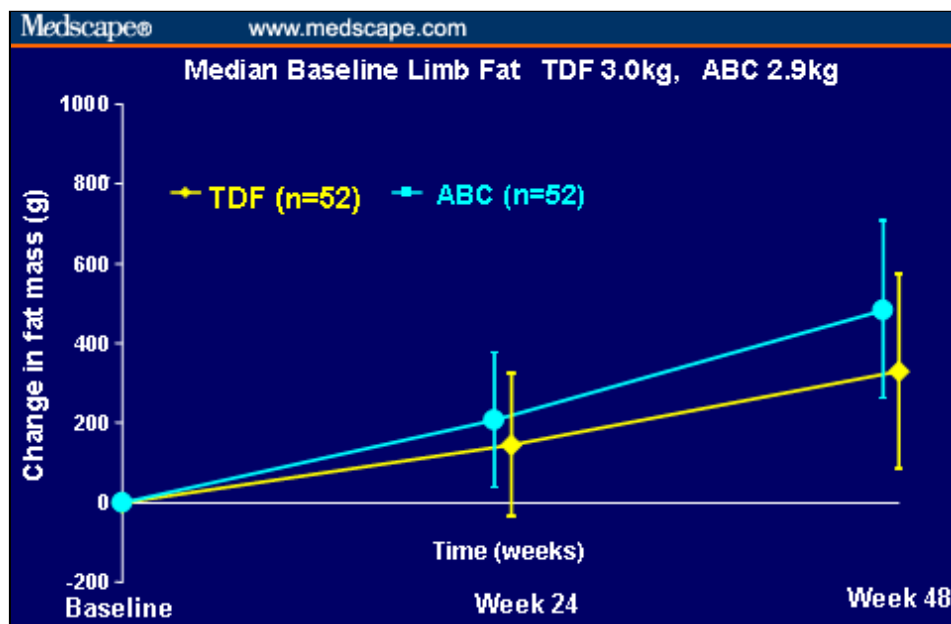
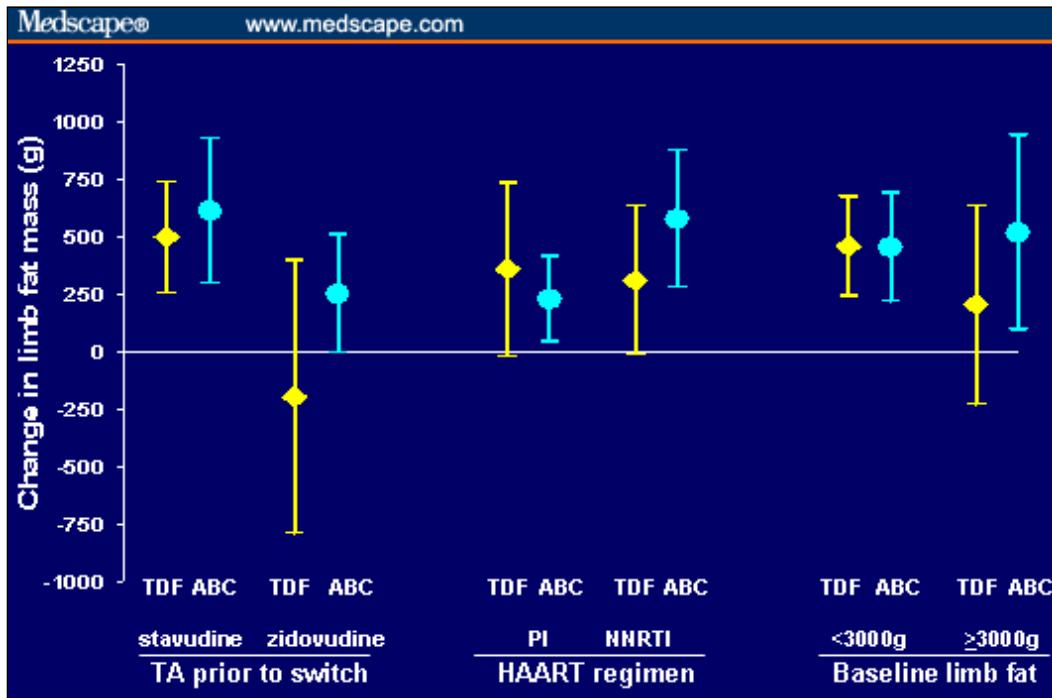
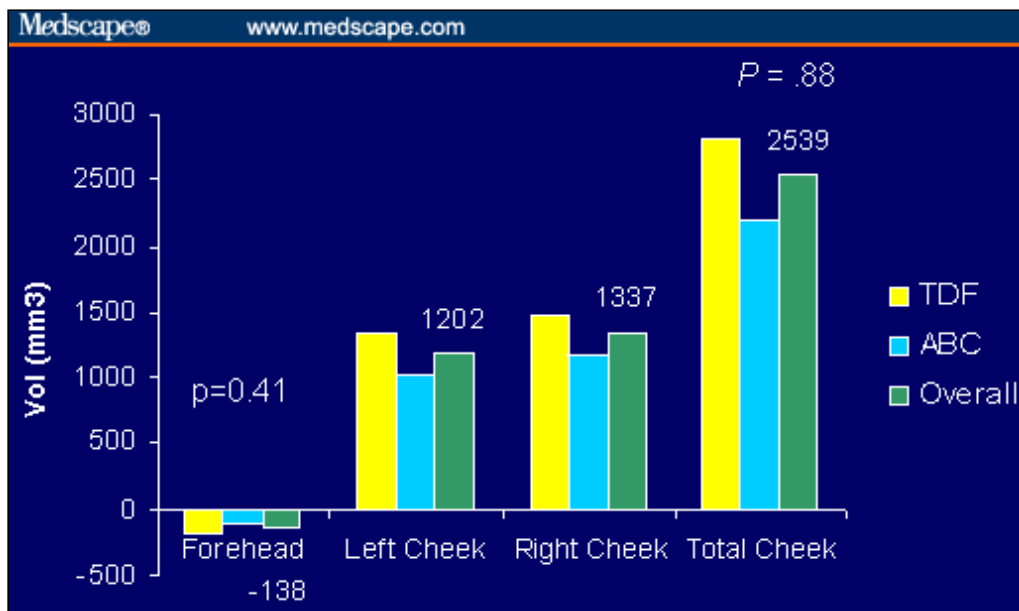


Figure 2. Mean change in limb fat at week 24 and week 48 in the RAVE

study.<sup>[2]</sup> (DEXA arm fat and total leg fat in grams: intent-to-treat, missing = failure analysis). Published with permission from Lippincott Williams & Wilkins (<http://lww.com>)



**Figure 3.** Mean changes in limb fat after switch ( $\pm$  interquartile range) at week 48 according to baseline antiretroviral drugs and limb fat in the RAVE study.<sup>[2]</sup> Published with permission from Lippincott Williams & Wilkins (<http://lww.com>)



**Figure 4.** Median change in volume after 48 weeks in the RAVE facial substudy measured by laser facial imaging.<sup>[3]</sup>

For those with established facial lipoatrophy who have modified therapy and are waiting for clinically evident fat recovery to occur, the process is at best slow and has an uncertain outcome. Prolonged treatment interruption (longer than 6 months) does not yield clinically evident improvements in lipoatrophy<sup>[4]</sup> and may risk disease progression events.

More recently a large, randomized, placebo-controlled study of pioglitazone 30 mg once daily has indicated a similar rate of limb fat recovery over 48 weeks to that observed in switch studies. However, the benefit was restricted to persons not receiving stavudine.<sup>[5]</sup> Other agents under investigation as lipoatrophy treatments include uridine and pravastatin.

### **Facial Fillers for Lipoatrophy**

The slowness, and in some cases apparent absence, of clinical recovery from lipoatrophy underscores the need for cosmetic surgical interventions for people with facial lipoatrophy. The agents used in these surgical approaches are known as implants or "facial fillers" (Tables 2 and 3). Evaluation of the potential of using fillers to enhance the buttocks or manage discomfort in feet has been very limited and largely unsuccessful.

Facial fillers may be natural (such as transferred fat) or synthetic, and they may be biodegradable (temporary) or nonbiodegradable (permanent). Of note, some "permanent" fillers may be wholly or partially removable. Fillers are necessary because of the loss of tissue mass from the lipoatrophy process. "Face lifts" cannot make up for lost tissue but merely tighten some of the skin that has become looser following the loss of tissue mass.

*[Editor's note: Because many clinicians who manage patients with HIV may be unfamiliar with many of these fillers, trade names and manufacturers are noted in Tables 2 and 3. In some cases in the text, trade names are used. This is because some fillers that are the same or similar in type/composition share a generic name, yet are sold under different trade names. Some of the studies that the author discusses were conducted with a particular branded product.]*

### **Biodegradable Agents**

Biodegradable agents (Table 2) are attractive in a situation in which there is the potential for recovery or partial recovery of the underlying condition, as has been suggested by the RAVE facial scan substudy.<sup>[3]</sup> The duration of benefit varies among agents, and there may be a need for "refilling" at a later time. Many of these

agents are generally best suited to filling mild-to-moderate areas of tissue loss.

**Table 2. Management of HIV-Associated Facial Lipoatrophy: Biodegradable Agents**

Product/Technique	Trade Name (Manufacturer)	Comment
Poly-L-lactic acid	<ul style="list-style-type: none"> <li>• <i>Sculptra</i> (Dermik)</li> <li>• <i>NewFill</i> (Ashford Aesthetics)</li> </ul>	<ul style="list-style-type: none"> <li>• FDA-approved for HIV-associated lipoatrophy (<i>Sculptra</i>)</li> <li>• Data from randomized studies</li> <li>• Requires multiple injections/sessions over many weeks</li> <li>• Benefits observed up to 3 years</li> <li>• Injections in buccal area show better results relative to temporal area</li> <li>• Nodule formation possible</li> </ul>
Hyaluronic acid	<ul style="list-style-type: none"> <li>• <i>Restylane</i> (Q Med)</li> <li>• <i>Perlane</i> (Q Med)</li> <li>• <i>Hylaform</i> (Inamed)</li> </ul>	<ul style="list-style-type: none"> <li>• Less injection volume/more sustained results relative to bovine collagen in filling nasolabial folds</li> <li>• Benefits observed up to 6 months in HIV lipoatrophy</li> </ul>
Fat transfer		<ul style="list-style-type: none"> <li>• Expensive</li> <li>• Patients with lipoatrophy often have inadequate fat to harvest and transfer</li> <li>• Transferred fat can be rapidly lost</li> <li>• Fat transferred from fat accumulation sites (eg, dorsocervical humps) may behave abnormally at the graft site</li> <li>• "Lumpy" results have been observed</li> </ul>
Calcium hydroxylapatite	<i>Radiesse</i> (Bioform)	<ul style="list-style-type: none"> <li>• In a prospective trial in HIV lipoatrophy, all patients showed improvements through 1 year, and most through 1.5 years.</li> <li>• Mild adverse effects</li> </ul>

**Poly-L-lactic acid (PLA).** PLA is an injectable bioabsorbable material for use in HIV-associated lipoatrophy. While all agents or procedures discussed in this brief review have been used off-label for management of lipoatrophy, PLA is the only agent that has a specific FDA indication for this condition.

The substance stimulates dermal fibroblasts to produce collagen, leading to thicker but natural-feeling skin. It is given as multiple subcutaneous or dermal injections. The injected area requires frequent massage in the days following injection to avoid nodule formation. Results in the temporal area are generally less satisfactory than those in the buccal area. It is immunologically inert, with inflammatory responses being very infrequent. PLA gradually reabsorbs over a 2- to 3-year

period, with benefits in HIV lipoatrophy reported over this period. Treatment is generally given in 3-5 sessions separated by 2-6 weeks, leading to a gradual change in facial appearance.

PLA has been evaluated in HIV lipoatrophy using a range of endpoints, both objective and subjective. At the Chelsea & Westminster Hospital in London, we randomized 30 persons with facial lipoatrophy to immediate and delayed treatment with PLA. The immediate-treatment group received 3 bilateral injections of 4-5 mL administered 2 weeks apart (weeks 0, 2, and 4) in the deep dermis overlying the buccal fat pad; the delayed-treatment group received injections at weeks 12, 14, and 16. Treatment was well tolerated, with adverse events limited to transient bruising in 1 patient and localized cellulitis in another. Assessments were made by facial ultrasound, visual analogue scales (VAS), and the Hospital and Anxiety Depression Scale at weeks 0, 12, and 24. At week 12, patients in the immediate-treatment group had significantly better VAS scores, lower anxiety scores, and trends toward lower depression scores compared with the control patients in the delayed-treatment arm. Benefits persisted through week 24, with the delayed-treatment group having similar benefits measured at that time. Many patients did not achieve complete resolution of their facial lipoatrophy.<sup>[6]</sup>

Longer term follow-up for a minimum of 18 months post treatment indicated that improvements in VAS scores for facial appearance ( $P < .05$ ) and trends to lower anxiety ( $P < .001$ ) relative to baseline were sustained. One case of injection-site induration (after 24 weeks) and 9 cases of injection-site nodules were noted.<sup>[7]</sup>

Various strategies have been suggested to decrease the risks and avoid the potential complications associated with PLA.<sup>[8]</sup> These include:

- higher volume dilution (8-12 mL/vial);
- fewer vials used at each session;
- injections placed in the subcutaneous plane without any going into the dermis;
- adequate time between injection sessions (at least 6 weeks); and
- postinjection patient massage.

Other larger but nonrandomized cohort studies have reported similar benefits to those of the Chelsea and Westminster study sustained through week 96, with a low frequency of adverse events.<sup>[9-13]</sup>

**Hyaluronic acid.** Hyaluronic acid is a polysaccharide component of mammalian soft tissue. These versions of hyaluronic acid are FDA-approved for the treatment

of wrinkles. Comparative trial data in general cosmetic surgery settings using treatment-blinded assessors have indicated that hyaluronic acid requires less injection volume and shows more sustained results relative to bovine collagen in filling nasolabial folds; therefore, hyaluronic acid may be better for filling deeper cutaneous defects.<sup>[14]</sup>

Hyaluronic acid has been used successfully to treat HIV facial lipoatrophy.<sup>[15]</sup> In general cosmetic practice, the benefits are expected to last about 6-12 months. In a series of 5 individuals with HIV lipoatrophy given 5-6 mL into the malar area, a good cosmetic result with sustained benefits through 6 months has been reported.<sup>[16]</sup>

**Fat transfer.** Fat transfer is an expensive and problematic approach as an intervention for HIV lipoatrophy. Many patients do not have fat elsewhere to transfer to facial areas. To further complicate matters, if the pathologic process that led to the fat loss is ongoing, the transferred fat can be rapidly lost. In contrast, fat transferred from fat accumulation sites such as dorsocervical humps may behave abnormally at the graft site and lead to disfiguring facial hypertrophy.<sup>[17]</sup> Cosmetically, lumpiness may be a problem.

The most commonly used technique for fat transfer is known as Coleman's method. Use of this technique has been reported in several cohorts of patients with HIV-related facial lipoatrophy. Durability for 6 months, and possibly up to 24 months, may be achieved.<sup>[18,19]</sup> In a series of 33 patients, independent assessors felt that only 12 (36%) of individuals had improved, although self-assessment by the participants showed that 14 (43%) were very satisfied and 17 (50%) were somewhat satisfied, with 27 (81%) reporting an improved quality of life.<sup>[20]</sup>

**Calcium hydroxylapatite.** Preparations based on calcium hydroxylapatite (CaHA) microspheres suspended in carboxymethylcellulose gel were first FDA-approved for vocal cord injections, for use in a range of orthopaedic surgery approaches, and in radiology (CaHA is radiopaque). However, this product has also been widely used for treatment of wrinkles and lip augmentation. CaHA is bioabsorbable over several years. Reported problems include hardening and overcollagenization requiring steroid injections.

In an 18-month, prospective, open-label, multicenter clinical trial of CaHA for facial lipoatrophy, all patients (N = 100) reported improvement in appearance at every time point through 12 months, and improvements were observed in 91% at 18 months. Skin thickness measurements at 12 months remained significantly better than those at baseline. Adverse events reported through 12 months were generally mild (bruising, edema, erythema, pain, and pruritus).<sup>[21]</sup>

## Nonbiodegradable Agents

**Silicone.** Several forms of liquid injectable silicone are FDA-approved for ophthalmic, but not cosmetic, uses. The American Society for Aesthetic Plastic Surgery has warned against the use of liquid injectable silicone for cosmetic purposes pending further investigation. Unfortunately, silicone oil injections can cause granulomas and long-term inflammatory changes and can migrate.

Several series and anecdotes report the use of liquid silicone for HIV-related lipoatrophy.<sup>[22-25]</sup> The use of highly purified 1000-cSt silicone oil injected by microdroplet serial puncture technique has been evaluated for the treatment of HIV-associated lipoatrophy. Data were reported on 77 individuals who were assessed as having achieved a complete correction. The volume of silicone, number of treatments, and time required to reach a complete correction were directly related to initial severity of lipoatrophy ( $P < .0001$ ). Supple, even facial contours were restored, with all patients tolerating treatments well. No adverse events were noted.<sup>[23]</sup> Although these data are encouraging, given the potential risks of silicone relative to alternative agents, and its permanence after injection, it is not a preferred treatment option.

**Expanded polytetrafluoroethylene (ePTFE).** These FDA-approved implants are more typically used for correction of craniofacial abnormalities (such as in nasal reconstruction) and after severe trauma, but can also be used for localized tissue augmentation. They can be inserted using a small incision while the patient is under local anesthesia. However, there are potential problems with lumpiness and physical obviousness of the implant. In general, adverse events, including movement, infection, swelling, induration, and uncommonly extrusion (emergence of implant through the skin), have been reported with cosmetic use of ePTFE implants.<sup>[26]</sup>

A case series on the use of ePTFE implants with or without polyacrylamide gel has recently been published.<sup>[27]</sup> A total of 90 consecutive persons with HIV-associated facial lipoatrophy were treated using implants alone in 11 cases, injections alone in 68 cases, and both implants and injections in 11 cases. Mean follow-up was 17 months for injections and 29 for implants. Adverse events included 3 cases of chronic inflammation and some lumpiness, which usually resolved over few months.

**Polymethylmethacrylate.** Polymethylmethacrylate (PMMA) in smooth microspheres suspended in bovine collagen is FDA-approved, but has no specific indication for HIV lipoatrophy. The bovine collagen in the implant is reabsorbed over time, but the presence of the PMMA microspheres generates new collagen production in that same site. It has been used in Europe for close to a decade and is available in other countries. A large series in Brazil described its use in HIV-

associated lipoatrophy, although clear systematic collection of safety data was lacking. Side effects reported included postinjection swelling and pain. Ultrasound data indicated an increase of dermal thickness sustained up to 5 years.<sup>[28]</sup>

**Polyacrylamide and polyalkylimide gels.** These agents are not FDA-approved but have been used in clinics in Europe (where they are approved) and Latin America. Some systematically collected data have been reported with *Bioalcamid* and *Eutrophill*. The different products have similar characteristics. They are relatively viscous and are injected subcutaneously. Following injection, the substances encapsulate, enabling at least partial removal (such as with a large-bore needle) at a later time. This characteristic makes them of interest for a condition that may partially resolve over time.

In a case series of 73 HIV-infected patients treated with *Bioalcamid* with up to 3 years of follow-up, "excellent" aesthetic results were reported with no episodes of implant dislocation, migration, granuloma, or allergic reaction recorded.<sup>[29]</sup> In a case series of 11 subjects with severe facial lipodystrophy, bilateral injections of 15 and 30 mL of a *Bioalcamid* gel into the buccal, malar, and temporal areas of the face were used.<sup>[30]</sup> The authors reported that all 11 subjects received an immediately acceptable aesthetic effect. Injections were generally well tolerated, with only 3 adverse events (swelling and bruising) recorded. Subjects, assessed at 3 and 18 months after treatment, continued to show improvement.

A series of 249 individuals treated with *Eutrophill* with up to 5-year follow-up reported good aesthetic outcomes, with 13 individuals having persistent asymptomatic papules at the injection sites and 2 patients reporting transient inflammatory events.<sup>[31]</sup> Recently, cases of infection, phlebitis, and ulceration around the sites of *Bioalcamid* injections have been reported in persons with HIV, and use of *Bioalcamid* in the buttock area has been associated with implant migration.<sup>[32]</sup>

**Table 3. Management of HIV-Associated Facial Lipoatrophy: Nonbiodegradable Agents**

Agent	Trade Name (Manufacturer)	Comments
Silicone oil		<ul style="list-style-type: none"> <li>• Favorable cosmetic data in lipoatrophy</li> <li>• Permanent</li> <li>• Granulomas, long-term inflammatory changes, migration are possible</li> <li>• American Society for Aesthetic Plastic Surgery has warned against liquid</li> </ul>

		injectable silicone for cosmetic purposes
Expanded polytetrafluoroethylene (ePTFE) implants	<ul style="list-style-type: none"> <li>• <i>Gore-Tex subcutaneous augmentation material (S.A.M.)</i> (W. L. Gore &amp; Associates)</li> <li>• <i>Advanta</i> (Atrium Medical)</li> </ul>	<ul style="list-style-type: none"> <li>• Case series data on implants ± polyacrylamide gel</li> <li>• Movement, infection, swelling, induration, and (uncommonly) extrusion have been reported.</li> </ul>
Polymethylmethacrylate	<ul style="list-style-type: none"> <li>• <i>Artefill/Artecoll</i> (Artes Medical)</li> </ul>	<ul style="list-style-type: none"> <li>• More extensive experience in Europe and elsewhere</li> <li>• Incomplete safety data in lipoatrophy</li> </ul>
Polyacrylamide and polyalkylimide gels	<ul style="list-style-type: none"> <li>• <i>Aquamid</i> (Contura)</li> <li>• <i>Bioalcamid</i> (Polymekon)</li> <li>• <i>Eutrophill</i> (Mediform)</li> </ul>	<ul style="list-style-type: none"> <li>• Not FDA-approved for HIV lipoatrophy, but approved in Europe and elsewhere for general cosmetic use</li> <li>• Case series data in lipoatrophy: favorable aesthetic results, minimal adverse effects</li> <li>• Some reports of infection, phlebitis, and ulceration around the sites of polyalkylimide implants</li> <li>• Buccal, malar, and temporal restoration possible; implant migration observed following implantation in buttocks</li> <li>• Partial removal possible</li> </ul>

## Comparative Data

Establishing endpoints is challenging for comparative studies of facial fillers that work by different mechanisms. Assessment by photographs may not lead to reproducible results and is operator-dependent, and the continuation of specific antiretroviral therapies may also influence outcomes. Fortunately, some attempts at comparison have been made, and funding for additional comparative data is being sought.

A 24-week comparative study of autologous fat transfer, PLA, and polyacrylamide hydrogel as fillers for HIV-related facial lipoatrophy has been reported.<sup>[33]</sup> The study was semi-randomized; individuals with enough residual subcutaneous fat in the abdomen or in the dorsocervical region were offered fat transfer, while other individuals were randomly assigned to 2 different surgical teams who administered

either treatment with PLA or polyacrylamide hydrogel injections every 4 weeks. The primary endpoint used was the dermal plus subcutaneous thickness measurement of Bichat's (malar) fat pad, as well as body image evaluations, facial aesthetic satisfaction by VAS, and aesthetic pre- and postpicture comparisons by independent reviewers.

Twenty-four individuals received fat transfer, 20 PLA, and 15 polyacrylamide hydrogel. The PLA and polyacrylamide hydrogel groups received a mean of 5 and 6 injection sessions, respectively. The mean change in dermal and subcutaneous thickness was  $3.3 \pm 4.1$  mm for fat transfer,  $3.5 \pm 4.0$  mm for PLA, and  $2.1 \pm 3.0$  mm polyacrylamide hydrogel ( $P = .687$ ) (Table 4). Serious adverse events occurred in 4 individuals in the fat transfer group, notably fat hypertrophy at the donor site.

**Table 4. Results: Comparative Study of Fillers for HIV-Related Facial Lipoatrophy**

Intervention	Mean Change in Dermal/Subcutaneous Thickness, mm*
Autologous fat transfer	3.3 ( $\pm$ 4.1)
PLA	3.5 ( $\pm$ 4.0)
Polyacrylamide hydrogel	2.1 ( $\pm$ 3.0)

\* $P = .687$

Comparative safety data are derived largely from the general cosmetic surgery literature.<sup>[34]</sup> In an international collaborative effort evaluating nodule formation and inflammatory events with synthetic injectable fillers, biopsies were contributed by various plastic surgeons from Europe and Australia. (It is important to note that these data were not derived from persons treated for HIV-associated lipoatrophy.) Data reported were based on:

- 5 biopsies from unreactive tissue obtained at different times after injection of polyacrylamide hydrogel (*Aquamid*);
- 28 biopsies from 20 individuals with intermediate or late inflammatory nodules after injection of polyacrylamide hydrogel (*Artecoll*);
- 2 cases of nodules following hyaluronic acid-polyhydroxyethylmethacrylate/ethyl methacrylate gel (*Dermalive*; Derma-Tech);
- 6 cases of nodules after PLA use (*NewFill*); and
- a review of the literature on adverse reactions after injection with permanent

fillers.

Clinically unreactive tissues after injection with polyacrylamide hydrogel showed modest or no host reaction. Inflammatory nodules showed an increased foreign-body reaction and a bacterial infection after injection with polyacrylamide hydrogel, and a combination of moderate foreign-body reaction, fibrosis, and in some cases also bacterial infection after injection with *Dermalive* and PLA (*NewFill*). Literature review suggested that inflammatory nodules are rare beyond 1 year after injection with polyacrylamide hydrogel, but may occur up to 6 years after injection of combination gels (*Artecoll*), and up to 28 years after injection of silicone gel. The authors concluded that inflammatory nodules are likely to be caused by a low-grade infection maintained within a biofilm surrounding silicone gel and the combination gels.

## Discussion

Case series and some limited controlled data indicate that treatment of HIV-associated facial lipoatrophy with facial fillers leads to good cosmetic results, improved psychological well-being, social functioning, and quality of life. Biodegradable fillers such as PLA are the most well-studied agents, but have the drawbacks of requiring multiple treatment sessions and the eventual need for "top-ups" in many patients. Permanent fillers are also of interest, particularly those agents that have the potential for partial removal. Fillers present a range of problems, most commonly postinjection pain and discomfort, and less commonly local infection and scarring. Comparative and systematically performed studies are needed to establish the best fillers for HIV-associated lipoatrophy.

*Supported by an independent educational grant from Gilead.*

## References

1. Collins E, Wagner C, Walmsley S. Psychosocial impact of the lipodystrophy syndrome in HIV infection. *AIDS Reader*. 2000;10:546-550. [Abstract](#)
2. Moyle GJ, Sabin CA, Cartledge J, et al. A randomized comparative trial of tenofovir DF or abacavir as replacement for a thymidine analog in persons with lipoatrophy. *AIDS*. 2006;20:2043-2050. [Abstract](#)
3. Benn P, Sauret V, Cartledge J, et al. Improvements in facial lipoatrophy at 48 weeks following substitution of a thymidine analog with tenofovir DF (TDF) or abacavir (ABC): a randomised, open-label study in persons with lipoatrophy and virological suppression on HAART. Program and abstracts of the 3rd IAS Conference on HIV Pathogenesis and Treatment; July 24-27, 2005; Rio de Janeiro, Brazil. Abstract TuPeLB2.3C02.
4. Hatano H, Miller KD, Yoder CP, et al. Metabolic and anthropometric consequences of interruption of highly active antiretroviral therapy. *AIDS*. 2000;14:1935-1942. [Abstract](#)

5. Maachi M, Slama L, Lanoy E, et al. Effect of pioglitazone on limb fat and circulating adipokines in HIV-related lipodystrophy. *Antivir Ther.* 2006;11:L16, abstract 23.
6. Moyle GJ, Lysakova L, Brown S, et al. A randomized open-label study of immediate versus delayed polylactic acid injections for the cosmetic management of facial lipoatrophy in persons with HIV infection. *HIV Med.* 2004;5:82-87. [Abstract](#)
7. Moyle GJ, Brown S, Lysakova L, Barton SE. Long-term safety and efficacy of poly-L-lactic acid in the treatment of HIV-related facial lipoatrophy. *HIV Med.* 2006;7:181-185. [Abstract](#)
8. Lam SM, Azizzadeh B, Graivier M. Injectable poly-L-lactic acid (Sculptra): technical considerations in soft-tissue contouring. *Plast Reconstr Surg.* 2006;118(3 suppl):55S-63S.
9. Lafaurie M, Dolivo M, Porcher R, et al. Treatment of facial lipoatrophy with intradermal injections of polylactic acid in HIV-infected patients. *J Acquir Immune Defic Syndr.* 2005;38:393-398. [Abstract](#)
10. Valantin MA, Aubron-Olivier C, Ghosn J, et al. Polylactic acid implants (New-Fill) to correct facial lipoatrophy in HIV-infected patients: results of the open-label study VEGA. *AIDS.* 2003;17:2471-2477. [Abstract](#)
11. Burgess CM, Quiroga RM. Assessment of the safety and efficacy of poly-L-lactic acid for the treatment of HIV-associated facial lipoatrophy. *J Am Acad Dermatol.* 2005;52:233-239. [Abstract](#)
12. Cattelan AM, Bauer U, Trevenzoli M, et al. Use of polylactic acid implants to correct facial lipoatrophy in human immunodeficiency virus 1-positive individuals receiving combination antiretroviral therapy. *Arch Dermatol.* 2006;142:329-334. [Abstract](#)
13. Barton SE, Engelhard P, Conant M. Poly-L-lactic acid for treating HIV-associated facial lipoatrophy: a review of the clinical studies. *Int J STD AIDS.* 2006;17:429-435 [Abstract](#)
14. Narins R, Brandt F, Leyden J, et al. A randomized, double-blind, multicenter comparison of the efficacy and tolerability of Restylane versus Zyplast for the correction of nasolabial folds. *Dermatol Surg.* 2003;29:588-595. [Abstract](#)
15. Ritt MJ, Hillebrand-Haverkort ME, ten Veen JH. Local treatment of facial lipodystrophy in patients receiving HIV protease inhibitor therapy. *Acta Chir Plast.* 2001;43:54-56. [Abstract](#)
16. Gooderham M, Solish N. Use of hyaluronic acid for soft tissue augmentation of HIV-associated facial lipodystrophy. *Dermatol Surg.* 2005;31:104-108. [Abstract](#)
17. Guaraldi G, De Fazio D, Orlando G, et al. Facial lipohypertrophy in HIV-infected subjects who underwent autologous fat tissue transplantation. *Clin Infect Dis.* 2005;40:e13-e15. [Abstract](#)
18. Caye N, Le Fourn B, Pannier M. Surgical treatment of facial lipoatrophy. *Ann Chir Plast Esthet.* 2003;48:2-12. [Abstract](#)
19. Strauch B, Baum T, Robbins N. Treatment of human immunodeficiency virus-

- associated lipodystrophy with dermafat graft transfer to the malar area. *Plast Reconstr Surg.* 2004;113:363-370. [Abstract](#)
20. Burnouf M, Buffet M, Schwarzinger M, et al. Evaluation of Coleman lipostucture for treatment of facial lipoatrophy in patients with human immunodeficiency virus and parameters associated with the efficiency of this technique. *Arch Dermatol.* 2005;141:1220-1224. [Abstract](#)
  21. Silvers SL, Eviatar JA, Echavez MI, Pappas AL. Prospective, open-label, 18-month trial of calcium hydroxylapatite (Radiesse) for facial soft-tissue augmentation in patients with human immunodeficiency virus-associated lipoatrophy: one-year durability. *Plast Reconstr Surg.* 2006;118(3 suppl):34S-45S.
  22. Talmor M, Hoffman LA, LaTrenta GS. Facial atrophy in HIV-related fat redistribution syndrome: anatomic evaluation and surgical reconstruction. *Ann Plast Surg.* 2002;49:11-17. [Abstract](#)
  23. Jones DH, Carruthers A, Orentreich D, et al. Highly purified 1000-cSt silicone oil for treatment of human immunodeficiency virus-associated facial lipoatrophy: an open pilot trial. *Dermatol Surg.* 2004;30:1279-1286. [Abstract](#)
  24. Orentreich D, Leone AS. A case of HIV-associated facial lipoatrophy treated with 1000-cs liquid injectable silicone. *Dermatol Surg.* 2004;30(4, pt 1):548-551.
  25. Webster RC, Gaunt JM, Hamdan US, et al. Injectable silicone for facial soft-tissue augmentation. *Arch Otolaryngol Head Neck Surg.* 1986;112:290-296. [Abstract](#)
  26. Brody H. Complications of expanded polytetrafluoroethylene (e-PTFE) facial implant. *Dermatol Surg.* 2001;27:792-794. [Abstract](#)
  27. Mole B. Lasting treatment of facial HIV and non HIV lipoatrophies through the use of SAM GoreTex malar implants and polyacrylamide hydrogel filler Eutrophill. About 90 consecutive cases. *Ann Chir Plast Esthet.* 2006;51:129-141. [Abstract](#)
  28. Oyafuso LK, Serra MS, Troppe BM. Polymethylmethacrylate (PMMA) for facial atrophy treatment: 5 years follow-up. Program and abstracts of the XV International AIDS Conference; July 11-16, 2004; Bangkok, Thailand. Abstract MoOrB1060.
  29. Protopapa C, Sito G, Caporale D, Cammarota N. Bio-Alcamid in drug-induced lipodystrophy. *J Cosmet Laser Ther.* 2003;5:226-230. [Abstract](#)
  30. Treacy PJ, Goldberg DJ. Use of a biopolymer polyalkylimide filler for facial lipodystrophy in HIV-positive patients undergoing treatment with antiretroviral drugs. *Dermatol Surg.* 2006;32:804-808. [Abstract](#)
  31. Carbonnel E, Mole B, Kazatchkine M, Claudy A. Long-term safety and efficacy of eutrophil for treatment of HIV-associated facial lipoatrophy. *Antivir Ther.* 2006;11:L60, abstract 99.
  32. Fontadella J, Martinez E, Guisantes E, Serra-Renom JM, Gatell J. Complications of Bioalcamid in the aesthetic treatment of lipoatrophy. *Antivir Ther.* 2006;11:L60, abstract 100.

33. Guaraldi G, Orlando G, De Fazio D, et al. Comparison of three different interventions for the correction of HIV-associated facial lipoatrophy: a prospective study. *Antivir Ther.* 2005;10:753-759. [Abstract](#)
34. Christensen L, Breiting V, Janssen M, Vuust J, Hogdall E. Adverse reactions to injectable soft tissue permanent fillers. *Aesthetic Plast Surg.* 2005;29:34-48. [Abstract](#)